



PATIENT PRESENTING CLINICAL SIGNS

Sandi Ritchie Bilateral nasal discharge- r/o chronic rhinitis, mass occupying mass (neoplasia/fungal), tooth abscess, FB - Sneezing - Moderate gingivitis - Grade 2 dental disease - Multiple SQ lipomas

SPECIES COMPUTED TOMOGRAPHIC STUDY OF THE HEAD

Canine Plain and post contrast studies are available for review.

COMPUTED TOMOGRAPHIC FINDINGS

BREED

Chihuahua

Moderate stenosis of the left external auditory meatus with moderate generalized thickening of the epithelial lining is seen. Mild luminal hypoattenuating material is noted. The right ear canal is unremarkable. No signs of otitis media are seen bilaterally.

SEX

FS

Mild to moderate bilateral nasal fluid and mucosal swelling is noted. There is no evidence of turbinate destruction, soft tissue masses, foreign material and no evidence of oral nasal communication.

The cribriform plate is intact.

AGE

11yr

Generalized atrophy of the alveolar margin is seen in all quadrants. Multifocal periodontal disease most pronounced at teeth 208 and 302 is seen. Multiple resorptive lesions notably associated with 104 are present throughout all quadrants.

INTERPRETED BY

Nele Eley (Ondreka),
DVM Dr. med. vet.,
DipECVDI

Mild bilaterally symmetric retropharyngeal lymphadenomegaly is noted.

COMPUTED TOMOGRAPHIC DIAGNOSIS

- Chronic left sided otitis externa with moderate ear canal stenosis, normal right ear, no otitis media
- Bilateral moderate signs of non-destructive rhinitis
- Multifocal periodontal disease and resorptive lesions with generalized alveolar bone atrophy
- Mild bilateral reactive retropharyngeal lymphadenitis

HOSPITAL NAME

Aloha Pet & Bird

INTERPRETATION OF FINDINGS & FURTHER RECOMMENDATIONS

REFERRING VET

Dr Lopez

The CT findings support chronic bilateral non-destructive rhinitis without evidence of neoplasia, fungal disease or foreign material. The periodontal disease may contribute to nasal and oral inflammation. Infectious or inflammatory rhinitis is considered likely. Further definition by means of rhinoscopy with sampling for C/S is recommended if not performed already.

INVOICE

23103

The left ear canal stenosis is consistent with chronic otitis externa and may require medical or eventual surgical management.

The lymph node changes are compatible with reactive lymphadenitis.

DATE

12/03/2025

Dental care addressing the periodontal disease and resorptive lesions is recommended as well.



PATIENT

Sandi Ritchie

SPECIES

Canine

BREED

Chihuahua

SEX

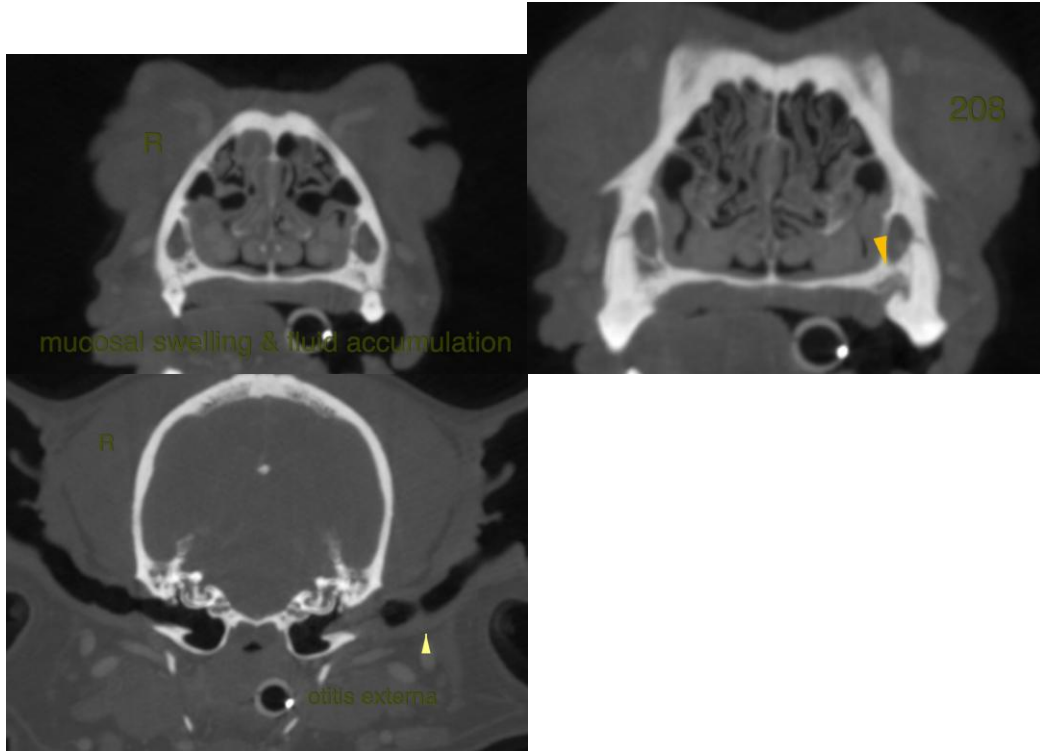
FS

AGE

11yr

INTERPRETED BY

Nele Eley (Ondreka),
DVM Dr. med. vet.,
DipECVDI



The information and recommendations provided are based on the images presented by the referring veterinarian. No evaluation can be communicated regarding pathology that was not visible in the image/video clips provided.

HOSPITAL NAME

Aloha Pet & Bird

Thank you for this referral. If the clinical or image interpretation does not parallel your findings or if I can be of any further assistance please contact me.

REFERRING VET

Dr Lopez

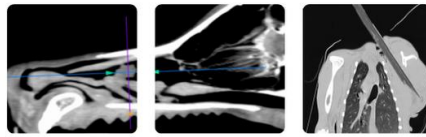
Nele Eley (Ondreka), DVM, Dr. med. vet., DipECVDI
European Specialist in Veterinary Diagnostic Imaging, Cert. Radiology,
Senior lecturer University of Giessen/Germany, Veterinary Faculty, Department of Radiology.
info@sonopath.com

INVOICE

23103

DATE

12/03/2025



PATIENT

Sandi Ritchie

SPECIES

Canine

BREED

Chihuahua

SEX

FS

AGE

11yr

INTERPRETED BY

Nele Eley (Ondreka),
DVM Dr. med. vet.,
DipECVDI

HOSPITAL NAME

Aloha Pet & Bird

REFERRING VET

Dr Lopez

INVOICE

23103

DATE

12/03/2025